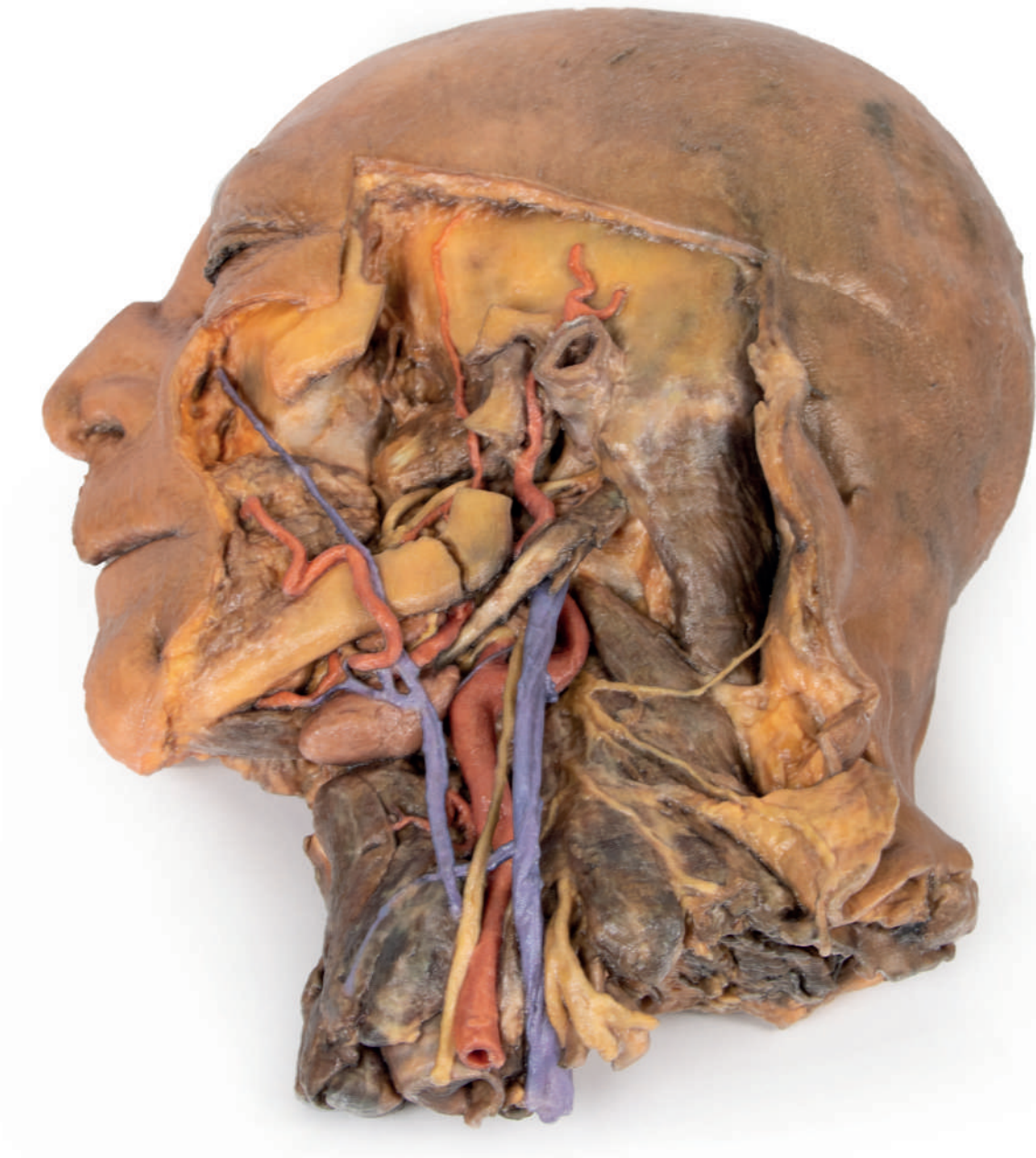


# Sagittal Section of Head and Neck with Infratemporal Fossa and Carotid Sheath Dissection



Ref.no.: MP1111

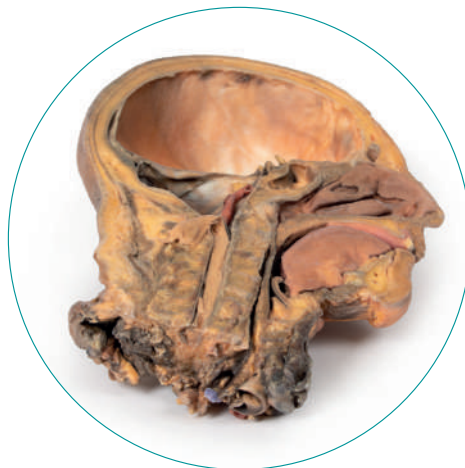## Sagittal Section of Head and Neck with Infratemporal Fossa and Carotid Sheath Dissection

This 3D model provides a complimentary specimen to the H 11 and H 12 head and neck specimens by providing a perspective of the endocranial cavity without the brain, and a lateral dissection inclusive of neck anatomy.

In the midsagittal section, the removal of the brain (and reflection of the medulla oblongata inferiorly) affords a full view of the dura mater lining the endocranial cavity, including the tentorium cerebelli spanning from the transverse sinus to the attachment to the clinoid process of the sphenoid. A series of cranial nerves, including the optic (CN II), oculomotor (CN III), trigeminal (CN V), the abducens (CN VI) and the combined facial (CN VII) and vestibulocochlear (CN VIII) nerves can be seen piercing the dura. The pituitary gland can be seen in cross-section within the sella turcica, and the left vertebral artery can be seen ascending in the posterior cranial fossa.

The lateral dissection to the face has retained some superficial structures while simultaneously exposing the anatomy within the infratemporal fossa. The facial vein and facial artery have been preserved but are dissected away from any superficial fascia or muscles of facial expression and lie across the corpus of the mandible and buccinator muscle. Most of the ascending ramus of the mandible and the zygomatic arch have been removed to demonstrate some of the infratemporal fossa anatomy, including the inferior alveolar artery and nerve and lingual nerve (resting on the medial pterygoid), the posterior deep temporal artery (resting on the lateral pterygoid), and the articulation of the mandibular condyle with the glenoid fossa. The terminal part of the external carotid artery is visible, as is the first part of the maxillary artery and the superficial temporal artery.

Posterior to the infratemporal region, the facial nerve (CN VII) can be seen briefly adjacent to the posterior belly of the digastric muscle. The posterior belly of the digastric angles superficially to obscure the internal and external carotid arteries and the internal jugular vein, which have been dissected from the carotid sheath (alongside the vagus nerve [CN X]). At the angle of the mandible, and along the inferior margin of the corpus, the hypoglossal nerve (CN XII) rests just adjacent to the central tendon of the digastric and the external carotid artery. Anteriorly, the facial artery is integrated into the submandibular gland before ascending across the mandibular corpus, where the lingual artery and anterior belly of the digastric can be observed. A set of superficial veins descend inferiorly into the neck as a presumptive external jugular vein (although displaced given the removal of



the retromandibular vein and sternocleidomastoid muscle, it is too posterior to be an anterior jugular vein).

In the neck region of the specimen, the hyoid bone is immediately deep to the submandibular gland and receives infrahyoid muscles just superficial to a robust thyroid gland. At the cut section of the dissection inferiorly, the underlying larynx can also be observed. Posterior to the carotid sheath structures, radiating cutaneous branches from the cervical plexus rest on the scalene muscles, and near the inferior margin of the specimen the upper roots of the brachial plexus are preserved adjacent to the exposed internal jugular vein.



