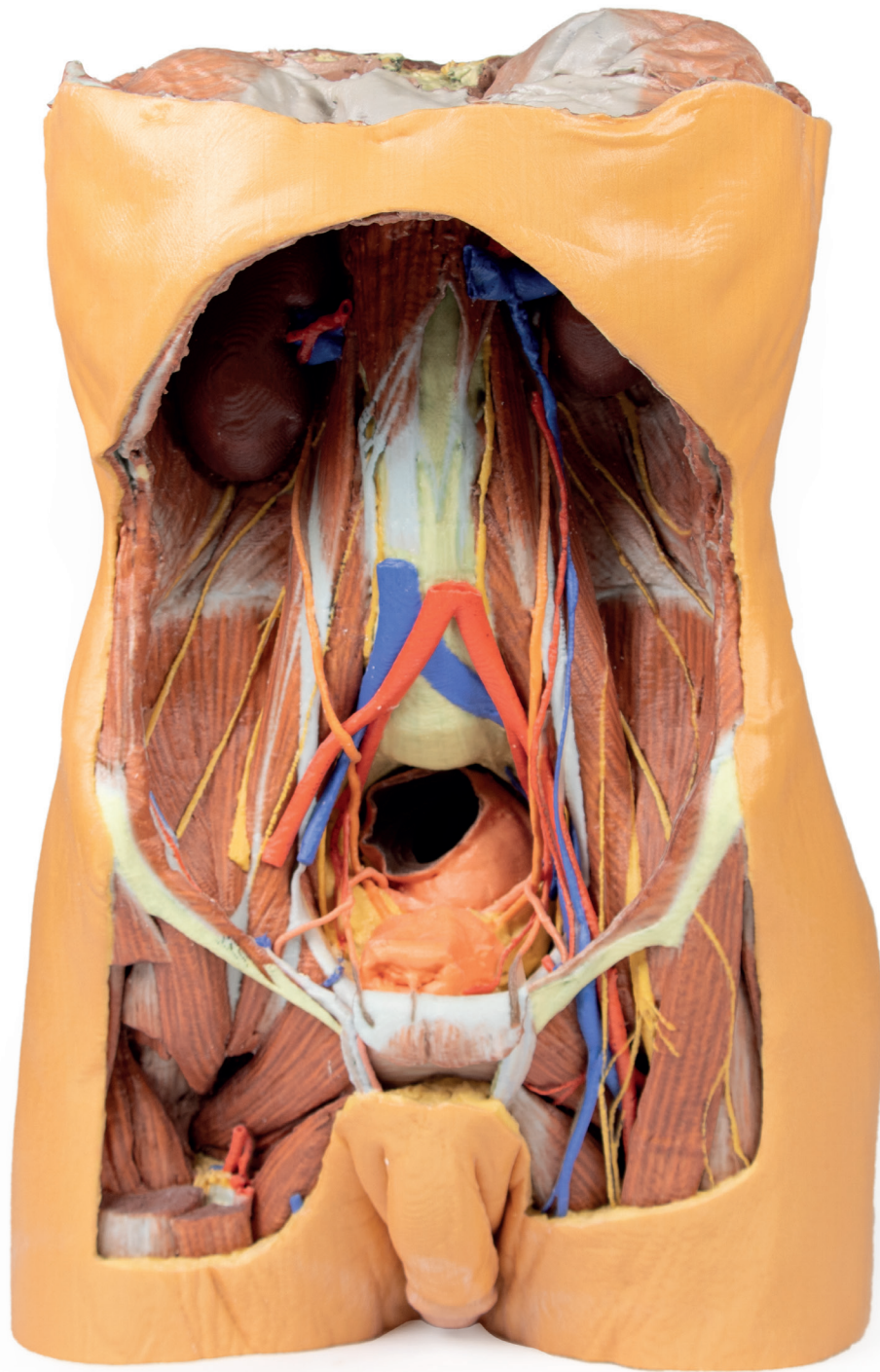


Posterior Abdominal wall



Ref.no.: MP1300

Posterior Abdominal wall

This large, multipart 3D printed specimen displays the entire male posterior abdominal wall from the diaphragm to the pelvic brim, as well as pelvic anatomy and to the proximal thigh. This same individual specimen is also available as a pelvic and proximal thigh specimen (MP1770).

The parietal peritoneum has been removed from the posterior abdominal wall to expose the muscular wall including the psoas, the quadratus lumborum, transversus abdominus, and the iliacus below the iliac crest. The muscular portions of the dome shaped diaphragm are clearly distinct from the central tendon. The fibres originate from the circumference of the internal walls of the bony thorax at its margin (sternal fibres, costal portion, lumbar portion). The origins of the diaphragm and the left and right crura are clearly identifiable originating from the vertebral bodies (L1-L3 on the right and L1-L2 on the left). The crura are connected by a tendinous band, the median arcuate ligament, which arches in front of the aorta; however in this specimen the aorta has been removed. The fibres of the diaphragm arising from the tendinous arches over psoas and the lateral arcuate ligaments are partly hidden by the kidneys. The oesophageal opening through the arching fibres of the right crus is present above (level of T10) and to the left of the aortic opening (level of T12). The opening in the central tendon that transmits the inferior vena cava (level of T8/9 intervertebral disc).

The somatic nerves of the posterior abdominal wall are clearly identifiable and consist of from above downwards – the subcostal, the iliohypogastric and ilioinguinal nerves lie on the quadratus lumborum (in this individual they arise together and – this can often occur and they split later in abdominal muscle layers), the lateral cutaneous nerve of thigh, the femoral lying in the groove between psoas and iliacus), and the genitofemoral nerve lying superficially upon psoas. The sympathetic trunks can be seen descending lateral to the lumbar vertebral bodies.

The aorta and inferior cava are transected around the level of L3 vertebral body. The aortic bifurcation into the right and left common iliac arteries is slightly higher than normal.

Finally, the kidneys have dissected from the peri- and pararenal fat of the posterior abdominal wall. The renal vessels (arteries anteriorly, veins posteriorly) have been preserved but as the aorta and inferior cava have been removed this does display the origin and arrangements of these vessels fully. The more inferior position of the right kidney is clearly visible and the ureters can be seen emerging from the hilum and descending initially lateral to psoas, then anterior to this muscle before crossing pelvic brim anterior to the bifurcation of the common iliac arteries to reach the true pelvis.

